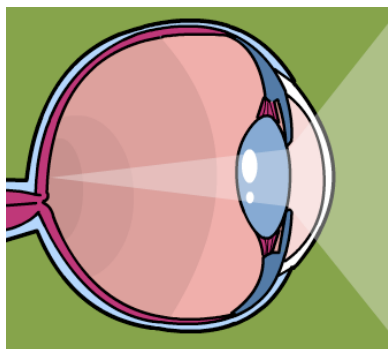





# Eye Anatomy and Surgery Crossword Puzzle



## Across

1. A new technique used for posterior corneal pathology is \_\_\_\_\_ endothelial keratoplasty (DSEK).
5. Farsightedness
10. Nearsightedness
11. \_\_\_\_\_ grafts can be used to treat a pathology in which the cornea is not of full thickness.
12. Natural aging of the eye
13. A slowly progressing corneal dystrophy that usually affects both eyes.

## Down

1. The cornea is composed of five layers: epithelium, Bowman's membrane, stroma, \_\_\_\_\_, and endothelium
2. Because the cornea is tissue that lacks \_\_\_\_\_, it can be transplanted at a 90% success rate.
3. Abnormal changes in the cornea that cause it to become more cone-shaped
4. Corneal transplantation is done to improve vision when the retina and \_\_\_\_\_ are functioning properly.
6. Magnifying bifocals are prescribed for \_\_\_\_\_ patients, usually after age 40.
7. \_\_\_\_\_ occurs when the cornea is cylindrically shaped instead of spherical.
8. Photorefractive Keratectomy (PRK) is performed if a patient has thin corneas, previous \_\_\_\_\_, or other corneal diseases
9. Medical name for corneal transplantation

*Reference: Alexander's Care of the Patient in Surgery, 15th edition*

**The National Institute of First Assisting, Inc.**  
 12354 East Caley Avenue, Suite 108, Centennial, CO 80111  
 1-800-922-7747 [www.RNFA.org](http://www.RNFA.org)